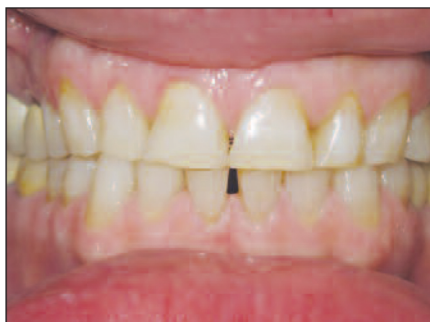
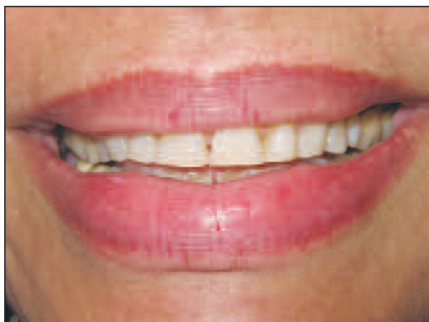

CASE SPOTLIGHT



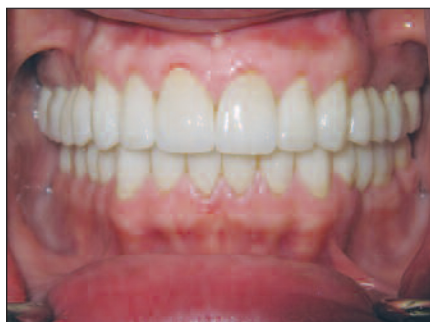Retracted view of initial situation.



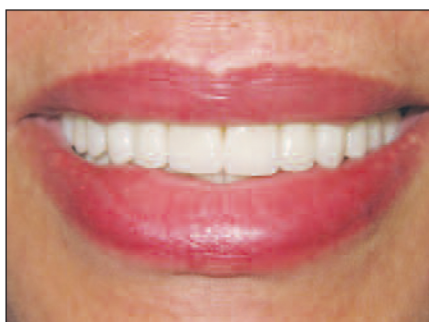Close-up of pre-operative Smile.




Full face Before.



Retracted view of corrected smile.



Close-up of new smile.



Full face After.

"Troubled by her severely worn dentition, phantom pain on #3 and breaking her porcelain restorations here and there, this patient (who also happens to be my mother) displayed the classic profile of a bruxer/clencher. Yet, she did not suffer from any TMJ pain. We started off by taking a full set of diagnostic x-rays and a TENS bite to determine her comfortable bite position, which showed she was overclosed by 3 mm. A Removable Lower Orthotic was placed for 5 months to correct the patient's jaw alignment and to calibrate proper vertical positioning, transitioning to a Fixed Lower LVI Orthotic for two months.

After conducting a K-7 neuromuscular study to ensure her new bite was comfortable and all of her neuromuscular symptoms were remedied, we discussed the concept of a full mouth restoration to restore a proper, functional vertical proportion and a complete smile makeover, which she eagerly accepted. Aurum Ceramic/Classic prepared a Diagnostic Wax-up as per their ACCES™ system. Her upper and lower arches were prepared and finished following the recommended LVI protocol for esthetic reconstruction with the Aurum Ceramic/Classic Advanced

Esthetic (AE) Team providing the Prep Indices and Bite Stent. A full set of temporaries was created from the wax-up from the bite transfer. All 28 teeth were restored at one appointment. The upper arch was restored with IPS Empress® Esthetic crowns (3-14) and single Contessa™ Crowns on #2 and #3, all beautifully crafted by Aurum Ceramic/Classic. The lower arch was restored with single Contessa crowns on #18, a Contessa bridge #19 - #21 and IPS Empress® Esthetic crowns on the remaining teeth. As the "After" photo shows, the texturing on this case is just beautiful and looks amazing. The restorations look truly natural. With a lot of texturing, when the light hits the moisture (i.e., saliva) on the dentition, it really gives the teeth dimension. Now, almost two years later, my mother is thrilled - she feels "like a new woman" and "looks 15 years younger." Not only does she have a beautiful new smile to compliment her beautiful face, she remains asymptomatic and no longer wears a nightguard! She is no longer bruxing and the phantom pain in #3 is gone."

Pamela Marzban, D.D.S.

Restorations fabricated by Aurum Ceramic/Classic.

Dr. Pamela Marzban graduated with a Doctor of Dental Surgery (DDS) with Honours/Distinctions from the Medical College of Virginia in 2000. Having grown up in Northern Virginia, she purchased a practice in Burke, VA in 2002 specializing in cosmetic dentistry, advanced implant technology and neuromuscular dentistry. A graduate of the Las Vegas Institute for Advanced Dental Studies, Dr. Marzban has completed Core curriculum and is currently completing the TMD course. She recently achieved FAGD status, is a Fellow in the Academy of General Dentistry, and a member of the American Academy of Cosmetic Dentistry, International Association of Comprehensive Aesthetics, American Dental Association, and Virginia Dental Association.